

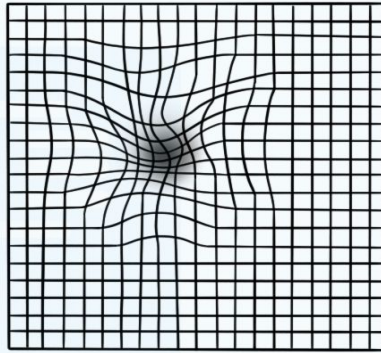
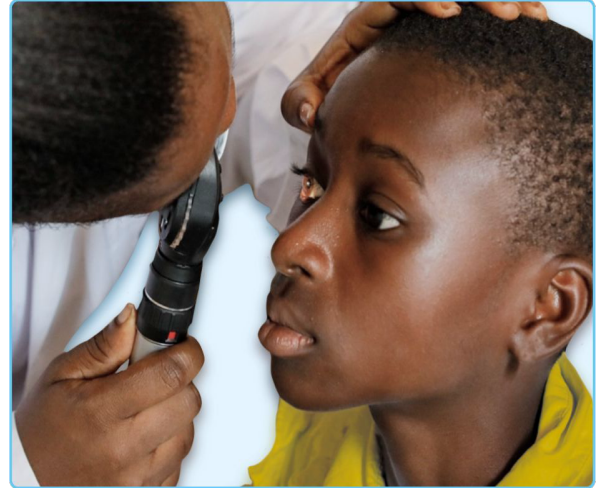

OPHTHALMOLOGY



Normal Vision



Vision with Wet
Macular Degeneration



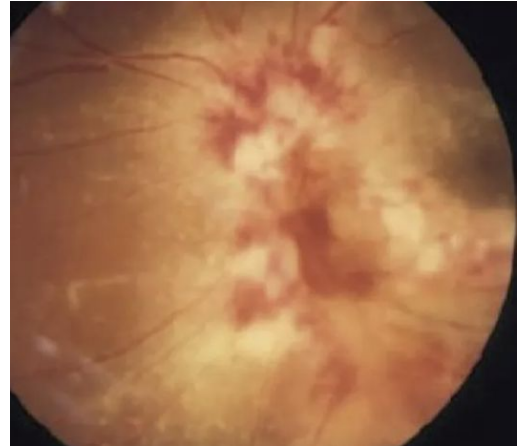1. AIDS patient presents with visual blurring. Fundus examination shows cottage cheese and tomato ketchup appearance. Which of the following is investigation of choice

- a. QNAT of aqueous humour
- b. QNAT of vitreous humour**
- c. QNAT of blood sample
- d. QNAT on corneal scraping

CMV →

Retinitis ✓ Pizza pie Retinopathy

NAT
qPCR
gancyclovir



2. A 5-year-old boy is hit in the eye with pencil in left eye while fighting with elder sister. 2 weeks later he develops photophobia and visual blurring in the contralateral eye. Which of the following is not correct about this condition?

- a. Dalen-Fuch nodules on slit lamp examination
- b. Earliest sign is retroental flare in non-injured eye
- c. Granulomatous panuveitis in non-injured eye
- d. Decreased power of accommodation ✓

DALEN FUCH nodules

↓
Bx HPE

* Sym. ophthalmias
↓
IL ciliary muscle #

CL blurring

O/E: Retroental flare

Rx: enucleation of
affected eye: < 2 wks

3. Which of the following investigations is best investigation about best disease?

- a. ERG showing arden ratio < 1.5
- b. ERG showing arden ratio > 1.5
- c. EOG showing arden ratio < 1.5
- d. EOG showing arden ratio > 1.5

* ERG: RODS & CONES
✓ EOG: RPE # (ROPE)

* EOG: $\frac{\text{PEAK light}}{\text{dark}}$ Ratio > 1.85

↓

↓

Vitelline
* macular
degeneration
B best 1
E egg yolk app^N
S subnormal EOG
T Teen onset

4. Most important determinant of development of diabetic retinopathy?

- a. Duration of diabetes
- b. Type of diabetes
- c. Severity of diabetes
- d. Level of glycemic control of diabetes *HbA1c value*

Sarcoidosis

5. Candle wax drippings on fundus examination are seen in which of the following?

- a. Young female with blurring of vision and loss of color vision MS: RAPD *
- b. Young male with HIV positive status and low CD4 count CMV_R marcus gunn pupil
- c. Young female with bilateral hilar lymphadenopathy and elevated ACE levels
- d. Young male with unilateral hilar lymphadenopathy and cavitation in lung
LTB

6. Sudden painless loss of vision in young female patient with fundus showing white retina with attenuated arterioles, cherry red spot and relative afferent pupillary defect is seen in which of the following?

- a. CRVO → Blood & Thunder app^N
- b. CRAO DLR ⊖, CLR + : RAPD
- c. Retinal vein occlusion
- d. Branched retinal vein occlusion HTN A-V nipping

7. Salu sign and Gunn sign on fundus examination is seen in which of the following patient?

- a. Hypertension
- b. Multiple sclerosis
- c. Neuromyelitis optica
- d. AIDS

* earliest: focal attenuation of arterioles

Purkinje Samson Images

8. Which of the following is not correct about basics of refraction in human eye?

- a. P III and P IV images are absent in aphakia ✓
- b. Maximum refraction is from anterior corneal surface ✓
- c. Streak retinoscopy reflex moves in same direction in myopia < 1D
- d. If axial length of eye changes by 3 mm then power changes by 1 dioptre
1mm ~ 3D

9. You are doing fundus examination in a child with diabetic mellitus with HbA1c of 10%. He complains of floaters in the eye. Which of the following is a pure mydriatic?

a. // Tropicamide ✓

b. Phenylephrine

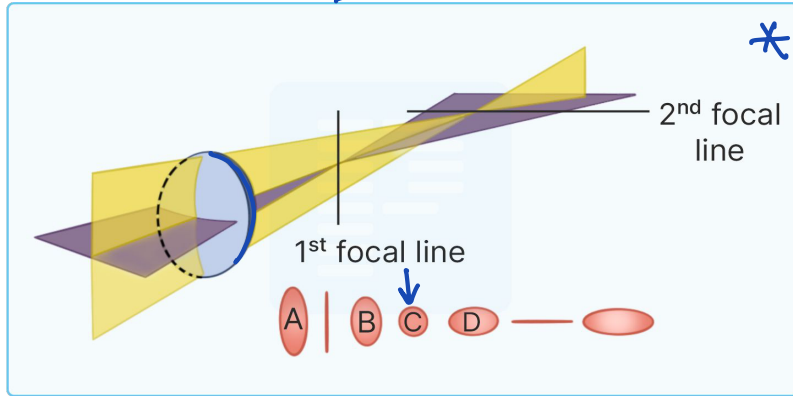
c. Cyclopentolate ✓

d. Homatropine ✓

✓ Cycloplegia → mydriasis
+
paralysis of accommodation

11. Which of the following shows circle of least diffusion:

- a. A
- b. B
- c. C
- d. D



Astigmatism

12. Which type of spectacle lens is suitable for sports persons?

a. Crown glass ✓

b. CR 39 plastic lens SCRATCH

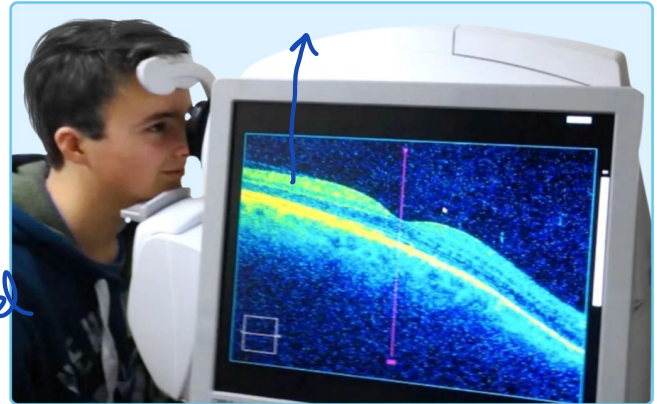
c. Polycarbonate

SCRATCH less, does not break easily

d. Polychromate SILVER

13. Which of the following is correct about the technique shown below

- a. Optical coherence tomography to study retinal nerve fiber layers
- b. Optical coherence tomography to study corneal topography *↖ Pachymetry*
- c. Optical coherence tomography to study corneal endothelial layer *↖ specular Corneal*
- d. Optical coherence tomography to study field of vision



microscope

14. 30-year-old female patient comes with markedly blurred vision and eye pain. On examination there is no discharge but extensive ciliary congestion is noted and cornea is hazy and pupil is vertically oval and fixed. Which of the following is correct about this case?


a. Anterior uveitis



b. Posterior uveitis

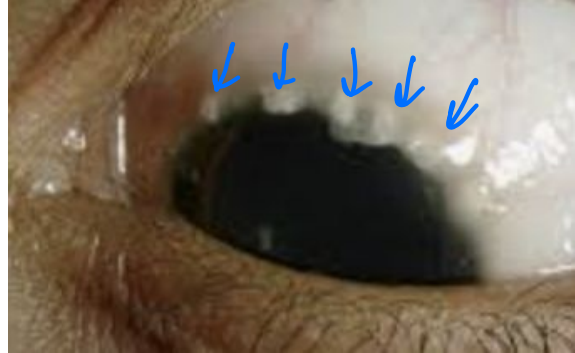c. Glaucoma

d. Trachoma



15. Horner tranta spots at the limbus are seen in

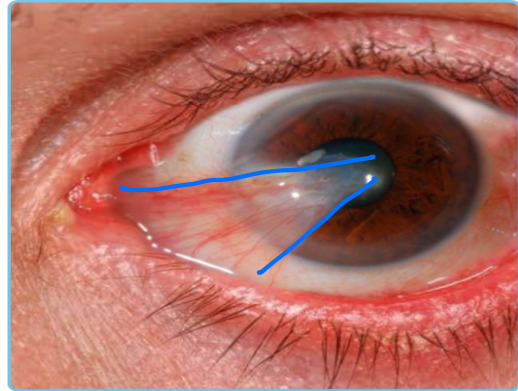
- a. VKC *Ropy discharge*
- b. Trachoma
- c. Giant papillary conjunctivitis
- d. Parinaud oculoglandular conjunctivitis



16. A patient presents with the following lesion. Which is not correct about it?

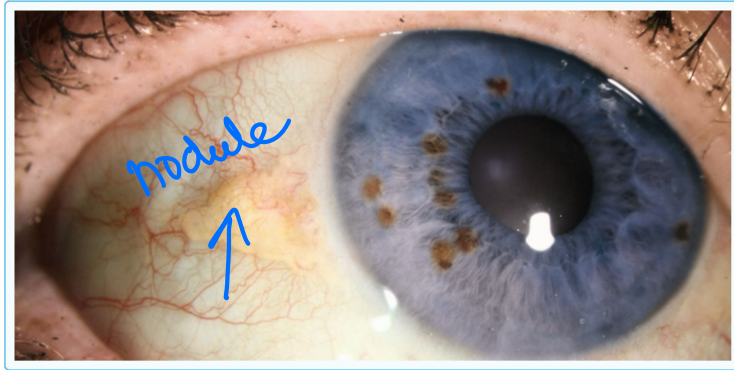
- a. Elastotic degeneration of collagen
- b. Stockers line with iron deposition is seen
- c. Astigmatism
- d. Yellow elevated triangular nodule adjacent to limbus

Pingecula

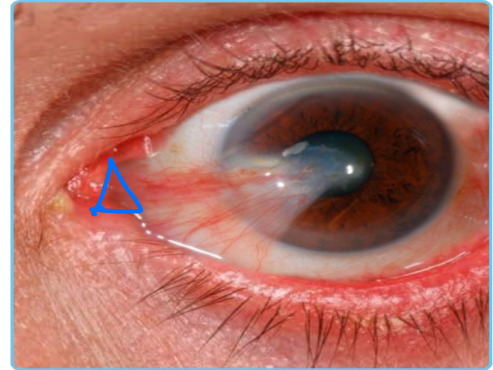


PTERYGIUM *

Pingecule *



mitomycin C drops

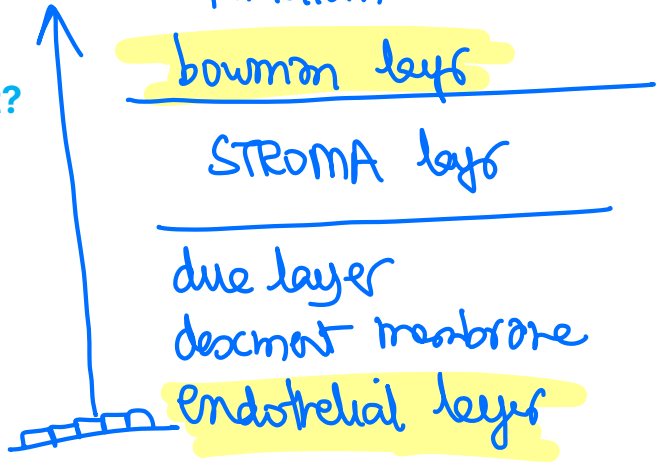


collagen 1,5

epitheliális

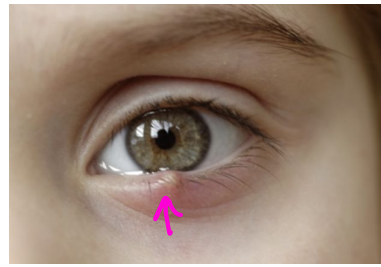
17. All are correct about layers of cornea except?

- a. Metabolically most active layer is endothelium ✓
- b. Collagen type 1 gives corneal transparency
- c. Bowman layer once eroded does not regenerate ✓
- d. Dua layer readily regenerates



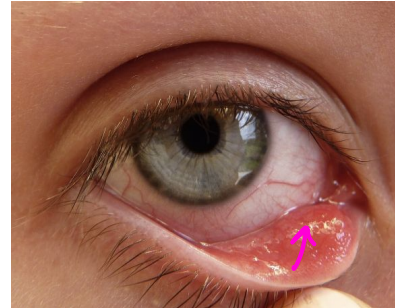18. Which of the following is correct about staphyloma?

- a. Local eye infection of meibomian gland by staph aureus
- b. Local eye infection of gland of Zeiss by staph aureus
- c. Local bulging of cornea lined by uveal tissue
- d. Local bulging of lens lined by uveal tissue



HORDEOLUM
EXTERNUM
(Stye)

* CHALAZION




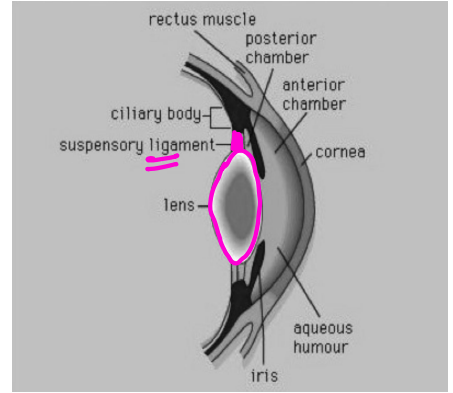
19. Which of the following is leading eye manifestation of rheumatoid arthritis?

- a. Uveitis
- b. Scleromalacia perforans
- c. Scleritis
- d. Keratoconjunctivitis sicca**

SCLERA

20. Which of the following is not correct about lens anatomy?

- a. Lens is least radiosensitive structure of eye
- b. Lens capsule is thickest membrane in the body
- c. Suspensory ligament of zinn connects the ciliary body to lens
- d. Yellowing of lens with age is due to accumulation of urochromes



21. Which of the following is the most visually debilitating cataract?

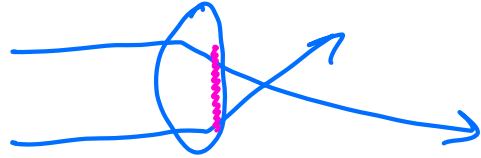
a. Anterior subcapsular cataract

b. Posterior subcapsular cataract

c. Syndermatotic cataract

d. Morgagnian cataract

STERIODS



22. Leading complication of cataract surgery is? ✓

- a. Endophthalmitis
- b. UGH syndrome
- c. Cyanopsia
- d. Posterior capsule opacification

life threatening complication
dreaded ↗

* glaucoma
increased in Myopia

WURSEN 2 (Mittel)



23. Inverse glaucoma is seen with which of the following?

- a. Weil Marchesani syndrome
- b. Homocystinuria HIN
- c. Aphakia
- d. Marfan syndrome MAST



dislocation

Watching in
movie in dark

* mydriasis

glaucoma

Rx: Pilocarpine

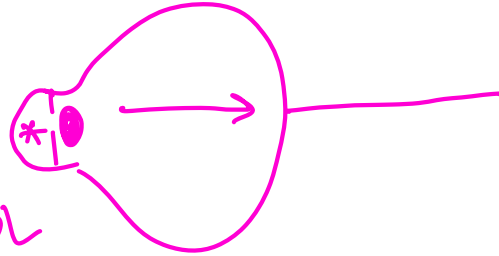
24. 50-year-old female comes with daily headaches, frequent change of presbyopic glasses with progressive visual loss. Slit lamp examination is normal and fundus shows vertically oval cupping of optic disc. Which of the following conditions is Likely responsible for this presentation?

- a. Mature cataract
- b. Hypermature cataract
- c. PACG

Shallow AC

- d. POAG

LANATOPROST + Timolol



25. Which of the following drugs acts by increase of aqueous outflow through direct action of trabecular meshwork and Schlemm canal cells?

- a. Prostaglandin analogs
- b. Rho kinase inhibitors
- c. Alpha adrenergic agonists
- d. Carbonic anhydrase inhibitors

=

Rock

Netarsudil

Rho kinase ⊖

↑ aqueous humor outflow

26. Which of the following is correct description of glaucoma caused by dislocation of lens into the Anterior chamber?

a. Phacomorphic glaucoma

change in shape *

b. Phacoanaphylactic glaucoma

c. Phacotopic glaucoma

change in position

d. Lens particle glaucoma


* POAG \Rightarrow Trabeculectomy

* PACG \Rightarrow LASER Iridotomy



PUPILLARY border *

27. Which of the following is not a feature of anterior uveitis?

- a. Koppe nodules on surface of iris and away from pupil *BUSACCA nodules*
- b. Seclusio pupillae are posterior synechiae
- c. Festooned pupil due to posterior synechiae ✓ 
- d. Aqueous cells due to disease activity ✓

28. Which of the following is best method to prevent acute postoperative endophthalmitis?

- a. Povidone iodine in conjunctival sac
- b. Saturated solution of potassium iodide in conjunctival sac
- c. Intra-viteal injection of ceftazidime and vancomycin
- d. Intra- viteal injection of meropenem and vancomycin

29. Which of the following methods is best for study of choroid vasculature?

a. Fundus optic disc | macula

b. Fundus fluorescein angiography → blood supply Retina

c. Indocyanine green angiography

d. Optical coherence tomography RPE

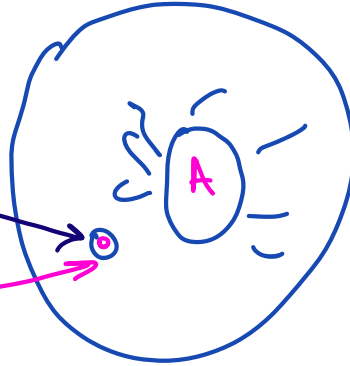
30. Most sensitive part of retina is?

a. Optic disc

b. Macula densa *kidney*

c. Macula lutea

d. Fovea centralis



*

→ CWS BIL, PANCREATITIS

31. Pseudo **purtscher's retinopathy** is seen in which of the following conditions?

- a. Head injury
- b. Chest trauma
- c. Fat embolism
- d. Best disease

32. Peaud orange appearance of retina is seen in?

- a. Purtschner retinopathy → CWS Bil
- b. Diabetic retinopathy → Neovascularization
- c. Tuberous sclerosis → MURBERRY Tumor
- d. Angioid streaks

33. Which is not a feature of Trachoma?

a. Trichiasis ✓

b. Entropion ✓

c. Alkaline tears ✓✓✓

d. Corneal opacity ✓

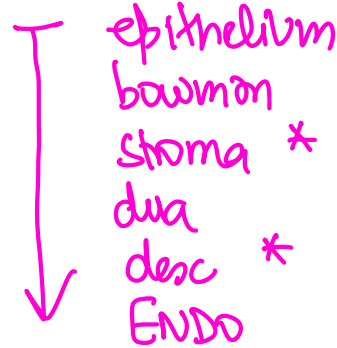
34. On slit lamp biomicroscopic finding, Fleischer ring is found in:

- a. Keratoconus
- b. Wilson disease
- c. Old corneal opacity
- d. Nebula

KF Ring

35. Dua's layer of cornea lies between?

- a. Substania propria and descemet membrane
- b. Descemet membrane and Endothelium
- c. Bowman layer and Substania propria
- d. Bowman layer and endothelium



36. Pannus formation is seen in?

- a. Herpes simplex keratitis
- b. Ulcus serpens
- c. Anterior staphyloma
- d. Riboflavin deficiency

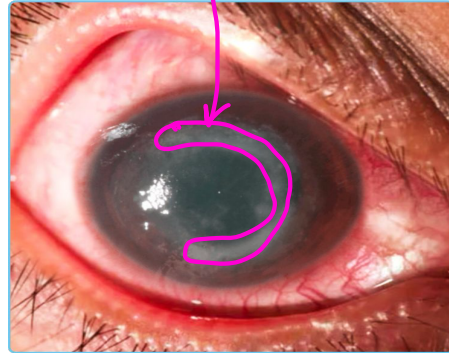
CIRCUMCORNEAL VASC

* ACANTHAMOBA KERATITIS

37. A 16-year-old girl using soft contact lens went for swimming lessons without removing the contact lens. After few days she is having severe pain in both eyes with corneal ring infiltrates and radial keratoneuritis. Which is best for management of this case?

- a. Change to hard contact lens
- b. Penetrating keratoplasty ✓
- c. Riboflavin eye drops
- d. Polyhexamethylene biguanide eye drops

PHMB



38. Uyemura's fundus is seen in? RODS # degeneration

- a. Retinal degeneration
- b. Retinal detachment
- c. Vitamin A deficiency
- d. Riboflavin deficiency

39. Earliest fundus finding of hypertension

- a. Cotton wool spots
- b. Micro aneurysm formation
- c. Focal attenuation of arterioles**
- d. Dot blot hemorrhages

HTN : focal attenuation
of arterioles

DM : microaneurysms

Vit A: Xanthopsia fundus

40. Alport syndrome leads to all of the following except? *

a. SN deafness ✓


b. Hematuria ✓

c. ESRD ↓

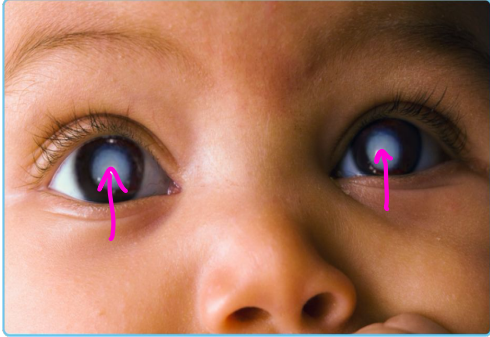
d. Posterior Lenticonus

* COL4A5 gene #

Anterior L



41. A baby born to TORCH positive mother is having the following presentation. Which of the following is the correct intervention for this child?



- a. Lens aspiration with IOL implantation within ~~4-6~~ months of life
- b. Lens aspiration with IOL implantation within 4-6 weeks of life
- c. Lens aspiration with IOL implantation after 6 weeks of life
- d. Lens aspiration with IOL implantation within ~~4-6~~ month of life

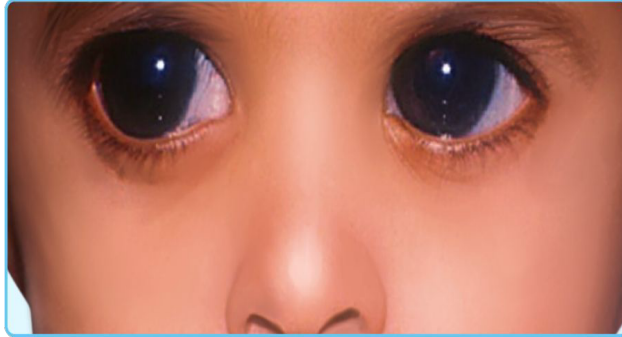CONGENITAL CATARACT

Sx

1° ↓
AMBYLOPIA

42. 1-year old boy has excessive lacrimation, photophobia and blepharospasm. Which is not correct about the condition shown?

- a. Haab striae ✓
- b. Hazy cornea ✓
- c. Myopia ✓
- d. Needs Drainage implants



Buphthalmos
Trabeculotomy
c
Trabeculectomy
Sx →

43. 2-day old Neonate is brought with bilateral copious purulent discharge with eyelid edema. Treatment is?

gonorrhoe

- a. Ceftriaxone
- b. Azithromycin
- c. Acyclovir
- d. Gentamycin

*

44. Relative afferent pupillary defect is seen in?

- a. Optic nerve glioma
- b. Iridocyclitis
- c. Brain stem stroke
- d. Pituitary adenoma

Retina ≠ CRAO
Optic Neuritis
Optic N. glioma
" meningioma

45. Patient presents with acute red eyes. Near and distant Vision is normal. which of the following is likely cause?

a. Acute Iridocyclitis



b. Angle closure glaucoma



c. Corneal abrasion

d. Acute conjunctivitis



46. Mitomycin C eye drops are used in management of?

- a. Pingecula
- b. Pterygium**
- c. Keratomalacia
- d. Post LASIK

47. Tubular vision is not seen in?

a. Retinitis Pigmentosa



b. High myopia

→ R.D peripheral



c. Pan-retinal photocoagulation

d. Advanced Glaucoma



48. Hudson Sthali line contains?

- a. Iron deposits
- b. Melanin deposits
- c. Copper deposits
- d. All of the above

✓
49. Blood and thunder fundus is seen in?

- a. Non ischemic CRVO
- b. Ischemic CRVO**
- c. Branch retinal vein occlusion
- d. Central retinal artery occlusion

50. Not a feature of triad of Retinitis Pigmentosa?

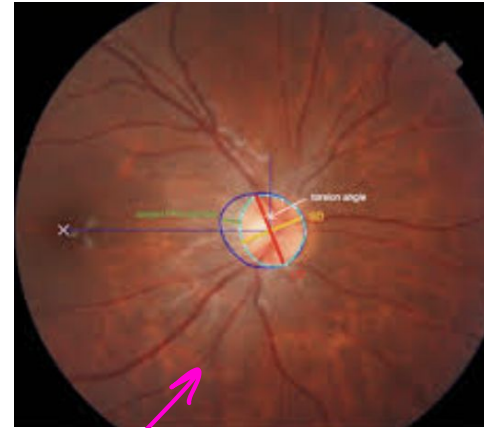
a. Arteriolar Attenuation ✓

b. Bone Spicule Pigmentation ✓

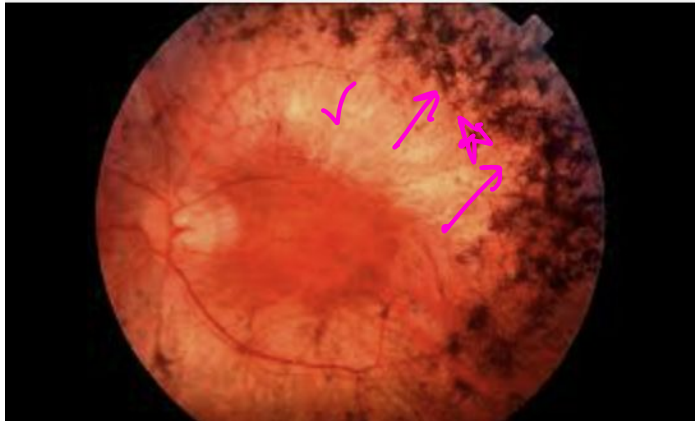
c. Waxy Pallor of optic Disc ✓

d. Tessellated fundus

Night blindness
= young ♂



Myopia



The tessellated fundus (also called "tigroid" or "mosaic" fundus) is an eye appearance where the large underlying choroidal blood vessels are visibly prominent through the retinal pigment epithelium

Neurosyphilis

Gumma

51. Site of lesion in Argyll Robertson pupil is?

- a. Optic nerve
- b. Retina
- c. Mid brain
- d. Occipital cortex



Accommodation

Reflex ⊕

pupillary Reflex ⊖

(2,3)

52. Cotton wool spots are found in which layer of retina?

- a. Retinal nerve fibre layer
- b. Outer plexiform layer
- c. Inner nuclear layer
- d. Retinal pigmentary epithelium

CORN

CWS: RNFL

MAIN
flameurpm
↓
INNER
NUCLEAR

53. Best for diagnosis of dry eyes is?

- a. Alcian blue
- b. Fluroscein dye *ULCER CORNEA*
- c. Rose Bengal dye
- d. Slit lamp biomicroscopy

54. Oil drop sign on direct ophthalmoscopy is seen in?

a. Galactosemia ← oil droplet cataract *

b. Keratoconus

c. Stromal keratitis

d. Menke disease

depth

55. Binocular vision with stereopsis in children is fully developed by?

- a. 6 months
- b. 1 year
- c. 7 year
- d. 10 years

56. All of the following lead to ptosis except?

a. M. Gravis ✓

b. Horner syndrome ✓

c. Third nerve palsy ✓

d. Grave's disease

EXOPHTHALMOS

*

57. The angle subtended at 6m for vision of 6/60 in Snellen chart is _____ minutes

- a. 5
- b. 10
- c. 20
- d. 50

$$\text{angle} = 5 \times \frac{x}{6}$$

✓
58. Donor cornea is harvested from cadaveric donors up to ___ hours?

a. 1

b. 2

c. 3

d. 6

✓
59. Vossius ring is seen on?

- a. Anterior lens capsule due to trauma
- b. Posterior lens capsule due to trauma
- c. Anterior lens capsule due to usage of ocular steroids
- d. Posterior lens capsule due to usage of ocular steroids



60. Retinopathy of prematurity is seen due to?

- a. Deficiency of oxygen
- b. Excess of oxygen**
- c. Deficiency of carbon dioxide
- d. Excess of carbon dioxide

61. Least radiosensitive cells in retina are?

- a. Rods ✓
- b. Cones ✓
- c. Ganglion cells
- d. Pigment epithelium ✓



62. Headlight in fog appearance on fundus examination is found in?

- a. Rubella
- b. CMV
- c. Best disease
- d. Toxoplasmosis



63. Diplopia on looking down is due to involvement of?



a. Superior oblique muscle

cheating muscle

b. Superior rectus muscle

c. Inferior rectus

d. Inferior oblique

64. Thinnest wall of orbital wall?


- a. Lateral wall
- b. Medial wall
- c. Roof
- d. Floor

LAMINA PAPYRACEUS

— Motion

65. Which of the following cells process information regarding ability to read slide below?

- a. Magnocellular cells
- b. Parvocellular cells
- c. Purkinje cells
- d. Pyramidal cell



Ishihara's charts

* Cerebellum

66. What does the image show?

CORNEAL lesion

a. Koeppe nodules



b. Dendritic keratitis

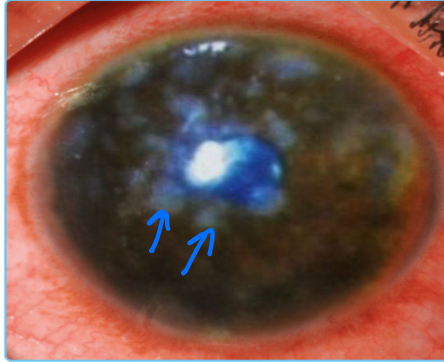


c. Lisch nodules

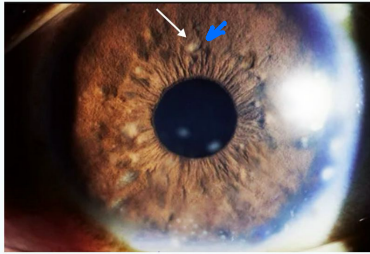
NF

d. Nummular keratitis

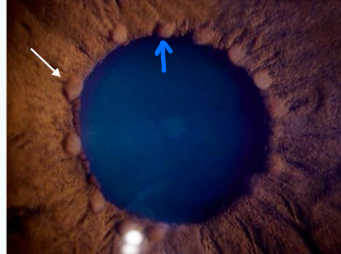
IRIS



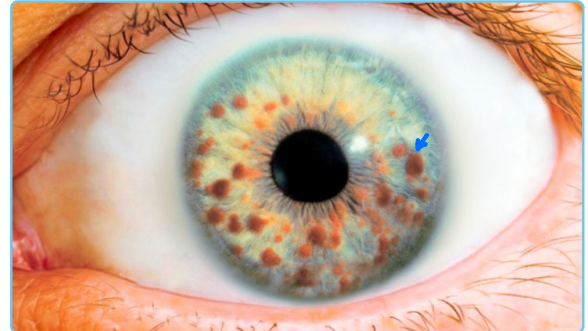- Nummular keratitis is a condition characterized by multiple, coin-shaped opacities (subepithelial infiltrates) in the cornea. It is typically a sign of an underlying viral or inflammatory condition, rather than a disease itself



Busacca's nodules:
on the surface of iris

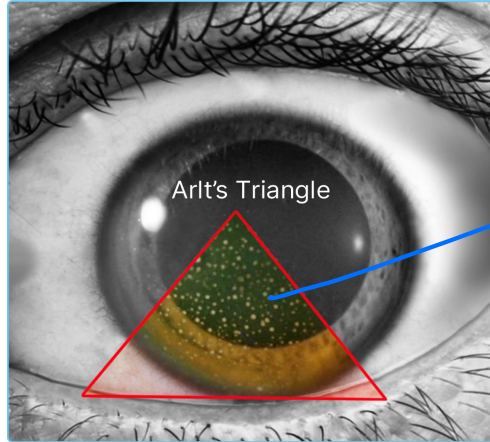


Koeppe's nodules:
at pupillary margin



67. Arlt triangle is seen with?

- a. Iridocyclitis
- b. Scleritis
- c. Sympathetic ophthalmitis
- d. Foster Fuch Kennedy syndrome



KP

68. During bridle suture during cataract surgery which muscle is likely to be injured?

- a. Inferior rectus
- b. Superior rectus
- c. Inferior oblique
- d. Superior oblique

↓
69. Absolute contraindication for LASIK is?

- a. Age <18 years
- b. Keratoconus
- c. Pregnancy
- d. Age > 50 years

70. A 50-year-old type II Diabetes mellitus patient with HbA1c = 11% has developed complete loss of vision in left eye. On examination a vitreous haemorrhage is noted. Which is the best treatment for managing this patient?

- a. Pan-Retinal photocoagulation
- b. Intra-Viteal Bevacizumab
- c. Resolves spontaneously
- d. Pars plana vitrectomy

71. Which cells of retina produce action potential?


- a. Outer plexiform
- b. Inner nuclear
- c. Ganglion cells
- d. Retinal pigmentary epithelium

72. 60-year-old woman went to cinema theatre to watch a movie with her grandchildren. Midway she experienced headache, blurring of vision and vomiting. On examination in E.R she has ciliary congestion with mid dilated vertically fixed pupil with poor reaction to light. GCS =13/15 and plantars are flexor. Which is the first step in management of this patient?

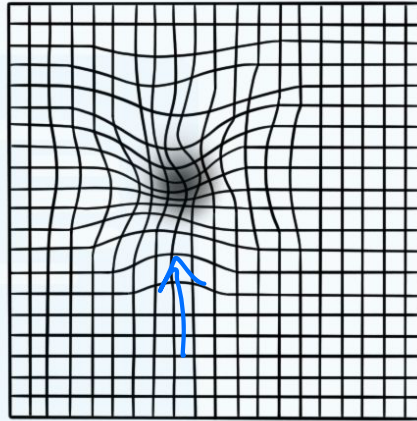
- a. Urgent fundus examination
- b. Osmotic diuretics ACG
- c. NCCT head
- d. Optical coherence tomography

73. Amsler grid is used to detect?

- a. Macular degeneration
- b. Optokinetic nystagmus
- c. Corneal topography
- d. Field of vision



Normal Vision



Vision with Wet
Macular Degeneration

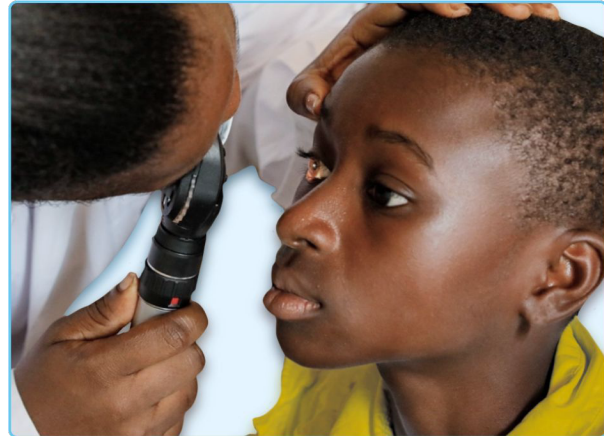74. Which is correct about this examination?

- a. Inverted real image ~~X~~
- b. Magnification 5 times ~~X~~
- c. ^{good} Good depth perception ~~X~~
- d. Area of field of focus is 2-disc diameters



DEV 15

: direct
ophthalmos



75. Deep anterior chamber on gonioscopy with open angles is seen in?

a. Iris bombe ACG

b. Phacolytic glaucoma

c. Phacomorphic glaucoma

d. Normal tension glaucoma

change in : shallow AC
shape

THANK YOU