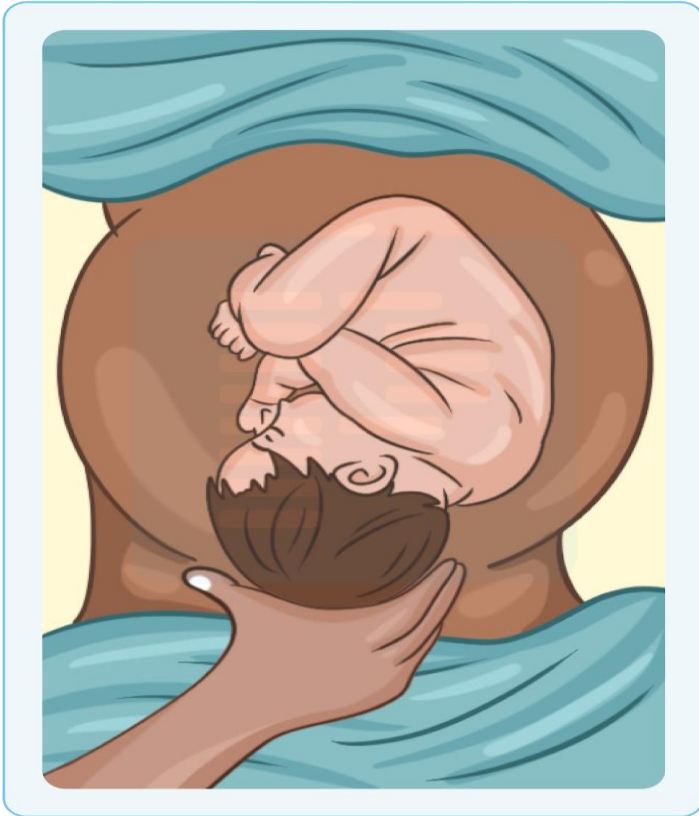

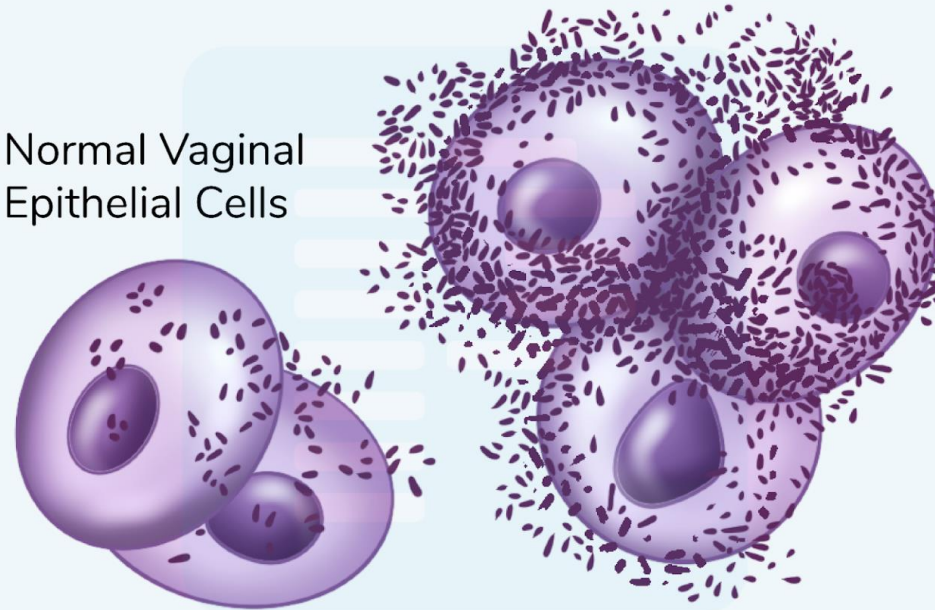


OBGY



Normal Vaginal Epithelial Cells



1. Fetal fibronectin test is primarily used for which of the following clinical purposes?

- a. Confirming fetal lung maturity
- b. Detecting premature rupture of membranes
- c. Predicting risk of preterm labor
- d. Screening for fetal aneuploidy

2. A 25-year-old primigravida is having severe abdominal pain in lower abdomen since today morning followed by two episodes of vomiting and prostration. In ER she says she noted spotting in the morning followed by sudden onset prostration. BP = 80/60 mm Hg and vaginal mucosa is blanched white. Which is best investigation to work up the case?

- a. Culdocentesis
- b. Blood grouping and cross matching
- c. Estimation of serum beta HCG levels
- d. Transvaginal scan

3. 32-year-old woman with severe preeclampsia is receiving magnesium sulphate infusion. She becomes drowsy, her respiratory rate drops to 6/min, Spo2 is 93% at room air and deep tendon reflexes are absent. What is the next best step?

- a. Reduce the infusion rate of magnesium sulfate
- b. Give calcium gluconate IV
- c. Start mechanical ventilation only
- d. Start supplemental oxygen 12L/min

4. What is the loading dose of magnesium sulfate in the Pritchard regimen for eclampsia?

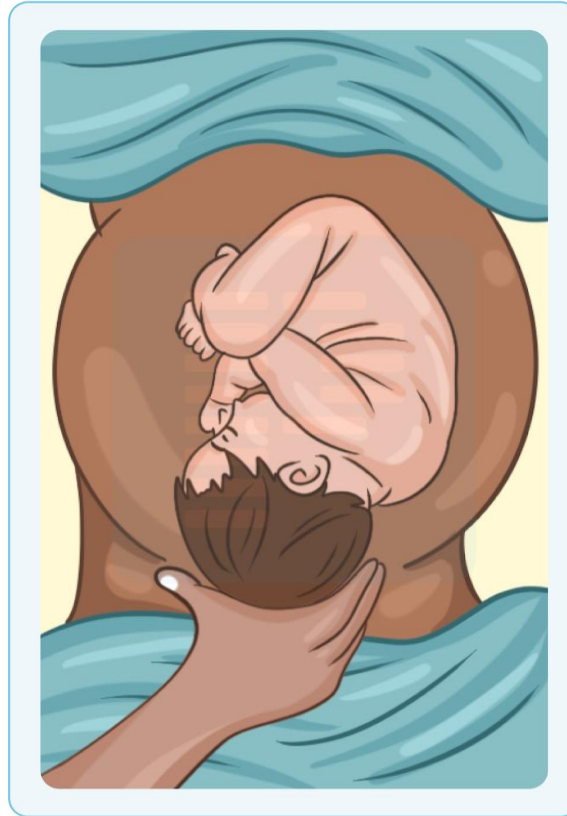
- a. 4 g IV + 5 g in each buttock
- b. 6 g IV + 4 g IM
- c. 4 g IV only
- d. 10 g IM only

5. Which of the following is correct about mechanism of normal labor?

- a. Flexion- internal rotation- crowning-extension- restitution
- b. Flexion- internal rotation- crowning-external rotation-restitution
- c. Internal rotation- Flexion- crowning-external rotation-restitution
- d. Internal rotation- Flexion - crowning-extension- restitution

6. Which of the following is correct about this obstetric grip?

- a. First Leopold maneuver
- b. Second Leopold maneuver
- c. First pelvic grip
- d. Second pelvic grip



7. HCG is synthesized by syncytiotrophoblast. Which of the following is not correct about it?

- a. Most sensitive test to detect is Fluorescence immunoassay
- b. Maximum levels are seen between 60-70 days of pregnancy
- c. Disappears from maternal urine within 2 weeks following delivery
- d. Increased levels are Hydatidiform mole

8. Which of the following can lead to fetal exsanguination?

- a. Placenta accreta
- b. Velamentous placenta
- c. Battledore placenta
- d. Placenta succenturiate

9. 25-year-old primigravida is detected with Amniotic fluid index of 3 cm on antenatal ultrasound at 32 weeks of gestation. Which of the following is not correct about this condition?

- a. Uterus is smaller than period of amenorrhea
- b. Breech malpresentation is common
- c. FHR decelerations caused by cord compression can be relieved by amnio-infusion
- d. Perform serial amniocentesis to relieve maternal distress

10. Which of the following test is best for assessment of fetal lung maturity in a primigravida with pre-existing type 1 Diabetes mellitus?

- a. L/S ratio > 2
- b. Detectable Phosphatidylglycerol
- c. Lamellar body count > 35000/uI
- d. Foam index of >0.47

L:S ratio is gold standard but is falsely high

11. 34-year-old pregnant woman at 36 weeks gestation feels dizzy, light-headed, and nauseated when lying flat during an ultrasound. Her BP drops from 110/70 to 80/50 mmHg. The most likely cause is:

- a. Aortic stenosis
- b. Inferior vena cava compression by gravid uterus
- c. Reduced plasma volume in late pregnancy
- d. Uteroplacental insufficiency

12. Which of the following changes during pregnancy is correct?

- a. Pituitary enlargement occurs by 125% due to estrogen
- b. Respiratory acidosis
- c. HDL levels fall by 50%
- d. Reduced minute ventilation

13. Which of the following signs is seen in acute PID?

- a. Oslander sign
- b. Chadwick sign
- c. Palmer sign
- d. Hegar sign

14. Which of the following components are not measured in manning score?

- a. Fetal breathing movements
- b. Fetal movement count
- c. Fetal scalp pH
- d. Amniotic fluid volume

15. Which of the following findings on CTG indicates uteroplacental insufficiency?

- a. Early deceleration
- b. Late deceleration
- c. Variable deceleration
- d. Early acceleration

16. Which of the following parameters will help in assessment of fetal anemia in erythroblastosis case?

- a. Serial fetal MCA velocimetry
- b. Reduced end diastolic flow in umbilical artery
- c. Absent end diastolic flow in umbilical artery
- d. Reversed flow in ductus venosus

17. Face to pubis delivery is more common with which of the following type of pelvis?

- a. Anthropoid
- b. Android
- c. Platypelloid
- d. Gynecoid

18. Which of the following diameters of pelvic inlet has shortest AP diameter?


- a. Diagonal conjugate
- b. True conjugate
- c. Obstetric conjugate
- d. Bispinous diameter

19. Which of the following is correct about Muller muro kerr method?

- a. Abdominal vaginal bimanual method for diagnosis of deep transverse arrest
- b. Abdominal vaginal bimanual method for diagnosis of Cephalo-pelvic disproportion
- c. Abdominal vaginal bimanual method for diagnosis of non-rotation of head
- d. Abdominal vaginal bimanual method for diagnosis of deep transverse arrest

20. Most common compound presentation is which of the following?

- a. Cephalic presentation with prolapse of hand
- b. Breech presentation with footling presentation
- c. Cephalic presentation with prolapse of shoulder
- d. Breech presentation with presentation of legs



21. Which of the following is not a sign of placental separation?

- a. Schroeder sign
- b. Kustner sign
- c. Permanent lengthening of cord
- d. Effacement of cervix

22. Leading cause of inversion of uterus is?

- a. Excessive cord traction with fundal attachment of placenta
- b. Excessive fundal massage
- c. Excessive dose of oxytocin and misoprostol
- d. Delayed cord clamping with excess dose of oxytocin at delivery of anterior shoulder

23. You are inspecting a perineal tear which shows laceration of posterior vaginal wall with perineal body excluding the anal sphincter. This corresponds to _____ perineal tear?

- a. First degree
- b. Second degree
- c. Third degree
- d. Fourth degree

24. 26-year-old G2P1 woman delivers vaginally after an uncomplicated labor. Ten minutes postpartum, she develops heavy vaginal bleeding and develops pallor, pulse =128/min and BP 90/60 mm Hg. Her uterus is boggy on palpation. Management is started with uterine massage, IV oxytocin infusion, misoprostol per rectum and carboprost. Despite these measures, she continues to bleed profusely. Two large-bore IV lines and fluids are running. What is the next best step in management of this patient?

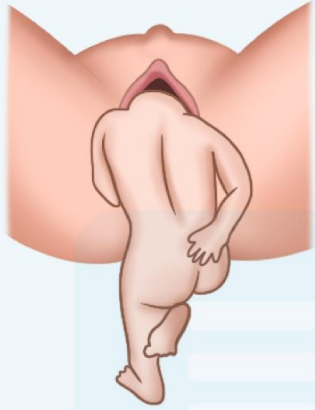
- a. Proceed to hysterectomy
- b. Start tranexamic acid infusion
- c. Perform internal iliac artery ligation
- d. Insert Bakri balloon

25. In Breech presentation the highest risk of cord prolapse is with which position?

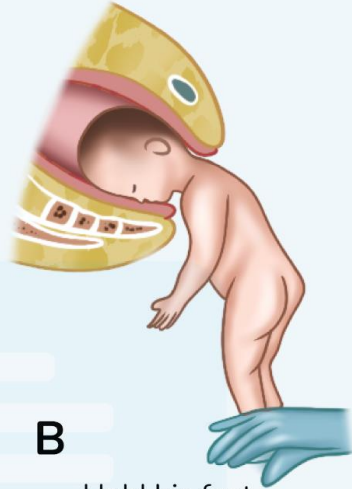- a. Footling presentation
- b. Breech with extended legs
- c. Frank Breech
- d. Star gazer position

26. Which of the following maneuvers is used for delivery of after coming head of breech:

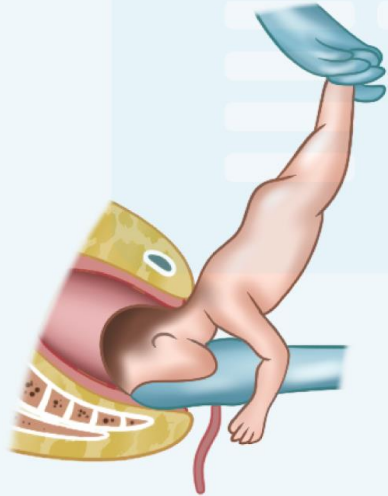
- a. Burns Marshall
- b. Lovset
- c. Pinard
- d. Duncan 's method



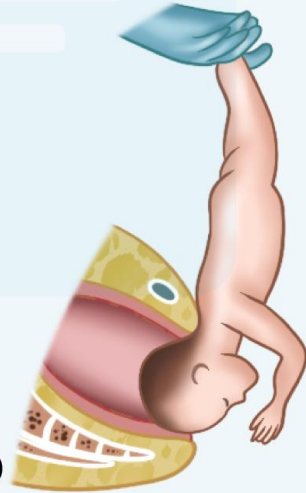
A Let him hang until the hair at the back of his neck is seen



B Hold his feet



C Free his mouth and suck him out



D Swing his head clear

27. Which of the following is not correct about occipito-posterior position?

- a. Common in anthropoid pelvis
- b. Deep transverse arrest can occur
- c. FHR heard in flanks
- d. MC cause of early engagement of head in primigravida

28. 25 years old primigravida develops bandl ring during delivery. CTG shows fetal heart rate of zero and the fetus is declared dead. Which is correct about management of this condition:

- a. Elective CS
- b. Emergency CS
- c. Decapitation of fetus and extraction
- d. Oxytocin drip and wait for active labor to expel the fetus

29. Which tocolytic agent is used in preterm labor acts by blocking oxytocin receptors

- a. Atosiban
- b. Isoxsuprine
- c. Magnesium sulphate
- d. Nifedipine

30. The leading chromosomal abnormality leading to abortion is?

- a. Trisomy 16
- b. Trisomy 21
- c. Trisomy 18
- d. Trisomy 13

31. Which color of escaping liquor alerts you to possible requirement of LSCS

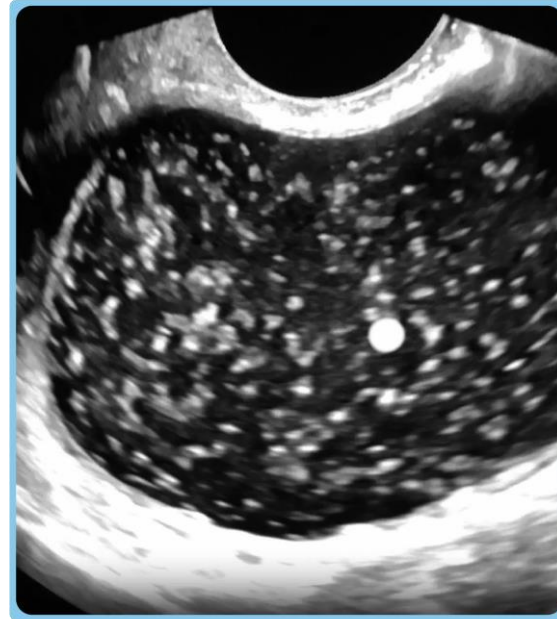
- a. Dark brown
- b. Green
- c. Golden
- d. Saffron

32. Which is correct about molding

- a. Crosses suture line
- b. Occurs in normal delivery due to compression of engaging diameter of head
- c. Occurs due to stagnation of fluid in layers of scalp below girdle of contact
- d. Occurs in cephalopelvic disproportion and changes in bi-mastoid diameter of fetal skull

33. A-35-year-old G4P3A0L3 lady with 12 weeks of amenorrhea presents with vaginal bleeding and has noticed some grape like vesicles expelled per vaginum with lower abdominal discomfort. On pelvic examination uterus is enlarged more than period of gestation and feels doughy. Cervix is favorable and FHS is not heard. Sonography report is shown below. Which is best management of this case?

- a. Suction evacuation
- b. Hysterectomy
- c. Hysterotomy
- d. Methotrexate



34. Absence of any measurable amount of amniotic fluid sonographically is called as?

- a. Oligohydramnios
- b. Anhydramnios
- c. Polyhydramnios
- d. Spontaneous rupture of membranes

35. Which of the following conditions in a pregnant lady will have least risk of maternal mortality?

- a. Coarctation of aorta
- b. Mitral stenosis with Dyspnoea grade IV
- c. Uncorrected Fallot's tetralogy
- d. Bioprosthetic valve

36. A 30-year-old primigravida lady has developed leakage per vaginum for last 24 hours at 32 weeks of gestation. Which complication can develop in the mother?

- a. Amniotic fluid embolism
- b. Complete abortion
- c. Chorioamniotitis
- d. Respiratory distress syndrome

37. 34-year-old nulliparous woman is having anemia. Menstrual history has irregular cycles with heavy bleeding. TVS and color doppler shows multiple fibroids in an enlarged uterus. All are true about this condition except?

- a. Centre of fibroid is least vascular and is likely to degenerate
- b. Cervical fibroids can kink the ureter
- c. Mifepristone is effective to reduce fibroid size and menorrhagia
- d. Subserous pedunculated fibroid is best diagnosed with Saline infusion sonography

38. Which is not a component of Meig syndrome


- a. Ascites
- b. Left sided Pleural effusion
- c. Brenner tumour of ovary
- d. Spontaneous resolution of ascites and pleural effusion on tumour resection

39. Which of the following is responsible for development of Pseudomyxoma peritonei?

- a. Mucinous cyst adenoma
- b. Peritoneal deposits from Serous cystadenocarcinoma
- c. Drop down metastasis from stomach cancer to ovary
- d. Theca lutein cysts

40. A 28-year-old lady presents with complaints of progressive dyspareunia and infertility. Bimanual examination reveals nodularity of utero-sacral ligaments and nodularity of pouch of Douglas with fixed retroverted uterus. Per speculum examination shows bluish spots on posterior fornix of vagina. Which of the following is the first differential diagnosis of this patient?

- a. Chronic PID
- b. Endometriosis
- c. Adenomyosis
- d. Cancer of endometrium



41. HPV triage strategy includes:

- a. Pap smear, HPV DNA PCR and colposcopy
- b. Pap smear, Cervicography and visual inspection with acetic acid
- c. Pap smear, cervicography and colposcopy
- d. Pap smear, Schiller test and Endocervical curettage

42. A 60-year-old woman with T2DM and Hypertension has presented with ulcer on vulva of 3 cm that she has been neglecting for last 4 months. Because of bad smell from ulcer and groin swelling she has come to your tertiary care hospital. You have advised biopsy which shows is to be Squamous cell cancer. MRI pelvis shows enlarged inguinofemoral nodes with extension of growth to lower 1/3 vagina. According to FIGO staging of carcinoma of vulva she is stage?

- a. I
- b. II
- c. III
- d. IV

43. 26-year-old lady with metallic prosthetic mitral valve is getting married next month. She is visiting your clinic with her fiancé today and seeks advise about tablets of anticoagulant she is using as they plan to start a family as early as possible. The strip of tablets she shows you from her purse is warfarin at dose of 0.5 mg per day. What is correct advice you would give her?

- a. Discontinue warfarin and start LMWH
- b. Continue warfarin and use barrier method
- c. Continue warfarin and use Progestin only pills
- d. Discontinue warfarin and start digoxin

44. Which of the following is not seen in infant born to lady with Gestational diabetes mellitus?

- a. Hypoglycemia
- b. Macrosomia
- c. Hypocalcemia
- d. Sacral agenesis

45. 30-year-old primigravida is having Hb= 9 gm% in second trimester with MCV of 110fl. What is next best step?

- a. Start parenteral iron supplementation
- b. Give Blood transfusion 2 units and then put on oral iron for remaining weeks
- c. Start Folic acid and B12 tablets
- d. Give oral iron only and monitor Hb after 4 weeks

46. The image shows?



- a. Ayre spatula for cervical scraping
- b. Rocket endocervical brush for endocervical sampling
- c. Wooden spatula for cyto-hormonal study
- d. Karman cannula

47. Which of the following methods of prenatal diagnosis has the highest fetal loss?

- a. Culdocentesis
- b. Amniocentesis
- c. Cordocentesis
- d. Chorionic villi sampling

48. Which of the following is *not* correct about management of epileptic lady on valproate who has delivered a perfectly healthy 3 kg girl baby in labour room of your hospital?

- a. Start breast feeding within 1st hour of birth
- b. Administer 1 mg vitamin K1 to neonate
- c. Check her pads for PPH
- d. Stop valproate and start Levetiracetam

49. Which is correct about Robert sign in case of IUFD?

- a. Appearance of gas shadows
- b. Hyperflexion of spine
- c. Irregular overlapping of cranial bones
- d. Crowding of ribs

50. Precipitate labour is present when?

- a. Combined duration of first and second stage of labour is less than 3 hours
- b. Combined duration of first and second stage of labour is less than 6 hours
- c. Combined duration of second and third stage of labour is less than 3 hours
- d. Combined duration of second and third stage of labour is less than 3 hours

51. Which is the rarest variety of cephalic presentation?

- a. Brow
- b. Breech
- c. Face
- d. Vertex

52. 35-year-old multigravida develops post-partum haemorrhage. Oxytocin drip was started by nurse. On examination by you her uterus is hard and contracted and cervical tear is noted at 6° clock position. Which is the best management for this case?

- a. Hysterectomy
- b. Ligation of uterine artery
- c. Bimanual compression
- d. Exploration of cervix and hemostatic sutures

53. Correct about oviduct?

- a. Sensitive to handling
- b. Lined by parametrium
- c. Normal position is anteverted and anteflexed
- d. Produces primary oocyte every 14th day of cycle

54. Which is correct about Braxton Hicks contraction?

- a. Lead to cervical dilatation
- b. Lead to cervical effacement
- c. Painless irregular contractions felt by mother during gestation
- d. Painful irregular contractions felt by mother during gestation

55. Rapid weight gain of > 0.5Kg per week in 25-year-old primigravida with sonography showing single viable fetus of 24 weeks gestation is suggestive of?

- a. Intrauterine growth retardation
- b. Intrauterine death
- c. Pre-eclampsia
- d. Multiple gestation

56. Which of the following parameter does not rise in pregnancy?

- a. Fibrinogen
- b. ESR
- c. Globulin
- d. Platelet count

57. Most conclusive clinical sign of pregnancy?

- a. Uterus palpable upto umbilicus
- b. Braxton hick contractions
- c. Uterine souffle
- d. Fetal heart sounds

58. Which diameter engages in face presentation?

- a. Sub-occipito-bregmatic
- b. Sub-occipito-frontal
- c. Mento-vertical
- d. Submento-vertical

59. Not present in quad screen?

- a. MSAFP
- b. uE3
- c. Inhibin B
- d. hcG

60. False about transverse lie:

- a. Shoulder presentation
- b. External cephalic version done before 35 weeks POG
- c. Grid iron feel on p/v examination
- d. Perform Cesarean section if ECV fails



61. Which of the following is not an effect of pregnancy on fibroids?

- a. Red degeneration
- b. Torsion
- c. Increase in size
- d. Infection

62. Which of the following is not used in PCOD?

- a. Human -chorionic Gonadotrophin
- b. Spironolactone
- c. Clomiphene
- d. Leuprolide

63. Which is correct about invasive cervical cancer?

- a. Exhibits trans-celomic spread
- b. Leading cause of death is due to mets to lungs
- c. Vaginal pool aspiration has diagnostic yield higher than cervical scraping
- d. It is an AIDS defining illness

64. 26-year-old sex worker presents with purulent urethral discharge. What is the best test for diagnosis?


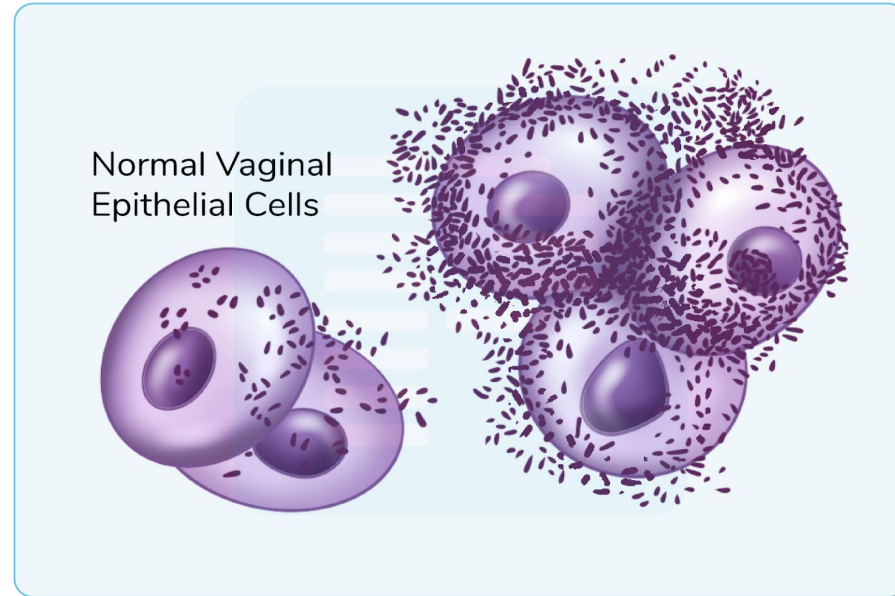
- a. N.A.A.T urine
- b. Urine culture
- c. Gram stain urethral discharge
- d. VDRL

65. Amsel Criteria is used for diagnosis of?

- a. Bacterial vaginosis
- b. Herpes Genitalis
- c. Syphilis
- d. Trichomonas vaginalis

66. Comment on diagnosis?

- a. Clue cells
- b. Tadpole cells
- c. Acantholytic cells
- d. Reed Sternberg cells



67. 26-year-old primigravida is having extensive itching in vulva with thick curdy white plaques seen in vaginal wall on Per speculum examination. Management is?

- a. Secnidazole vaginal pessary
- b. Clindamycin vaginal pessary
- c. Single dose ceftriaxone
- d. Clotrimazole vaginal pessary

68. Oophoritis is seen with?

- a. Mumps
- b. Fitz Hugh Curtis syndrome
- c. Measles
- d. PCOS

69. Reservoir of Chlamydia infection?

- a. Ectocervix
- b. Endocervix
- c. Fallopian tube
- d. Ovary

70. Best management of Pre-menstrual syndrome is?

- a. SSRI
- b. OCP
- c. Danazol
- d. Metformin

71. Not a cause of contact bleeding?

- a. Carcinoma cervix
- b. Mucous polyp of cervix
- c. Subserous fibroid
- d. Cervical endometriosis

72. Most common benign solid ovarian tumour is?

- a. Fibroma
- b. serous cystadenoma
- c. Granulosa cell tumour
- d. Krukenberg tumour

73. Triad of adnexal mass, post-menopausal bleeding and watery discharge P/V is seen in?

- a. Ovarian tumours
- b. Fallopian tube cancer
- c. Cervical cancer
- d. P.I.D

74. Burch colpo-suspension is used for management of?

- a. Uterine prolapse
- b. Vesicovaginal fistula
- c. Stress incontinence
- d. Procidentia

75. Three swab (Tampon) test is used of diagnosis of?

- a. Uterine prolapse
- b. Vesicovaginal fistula
- c. Stress incontinence
- d. Procidentia



THANK YOU