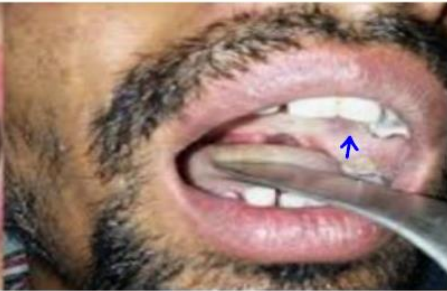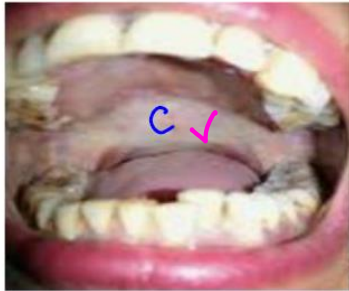

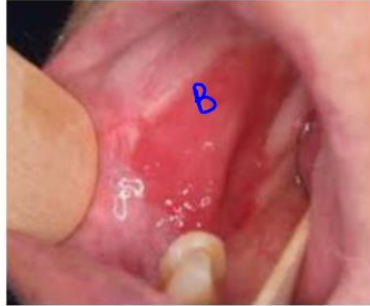
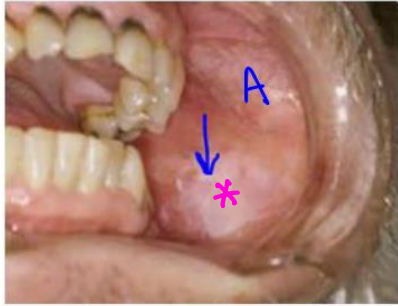Lesions of oral cavity

Lesions of oral cavity



Pre-malignant lesions

A

leukoplakia

B

Erythroplakia: 17x ↑

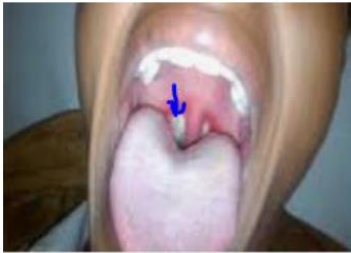C

oral submucosal
Fibrosis

(Betel nut)

Miscellaneous conditions

6 yrs Miscellaneous conditions



FEVER

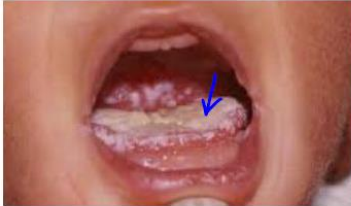STRIDOR, SOB

GRAY-WHITE: Pseudomembrane, bleeds on removal

FAUCIAL DIPHTHERIA

* death \Rightarrow myocarditis

LARYNGEAL "



HIV (+) MOTHER $\xrightarrow{30\%}$ infant
Vx Transmission

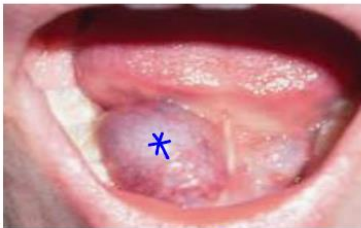CURD-LIKE

LESION(S) oral cavity:

CANDIDA

oropharyngeal

Rx: gentian violet / Clotrimazole gel



RANULA Floor OF mouth

LUDWIG ANGINA: Cellulitis of floor of mouth

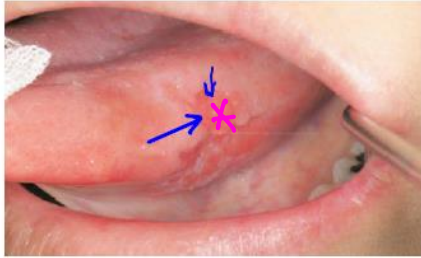
Pre-malignant lesion of oral cavity

1. Oral submucosal fibrosis
2. Leukoplakia
3. Erythroplakia
4. Hyperplastic candidiasis

global BASIC ↓

MC type of oral cancer: SCC

MC site of oral cancer: LATERAL BORDER of Tongue



* MC site of oral cancer in India: Buccal mucosa | Cheek

Site of carcinoma lip: VERMILION BORDER

